

PROVA PRATICA N. 1

FIBRILLAZIONE ATRIALE: paziente di 80 anni si presenta in pronto soccorso per cardiopalmo.

16/09/24

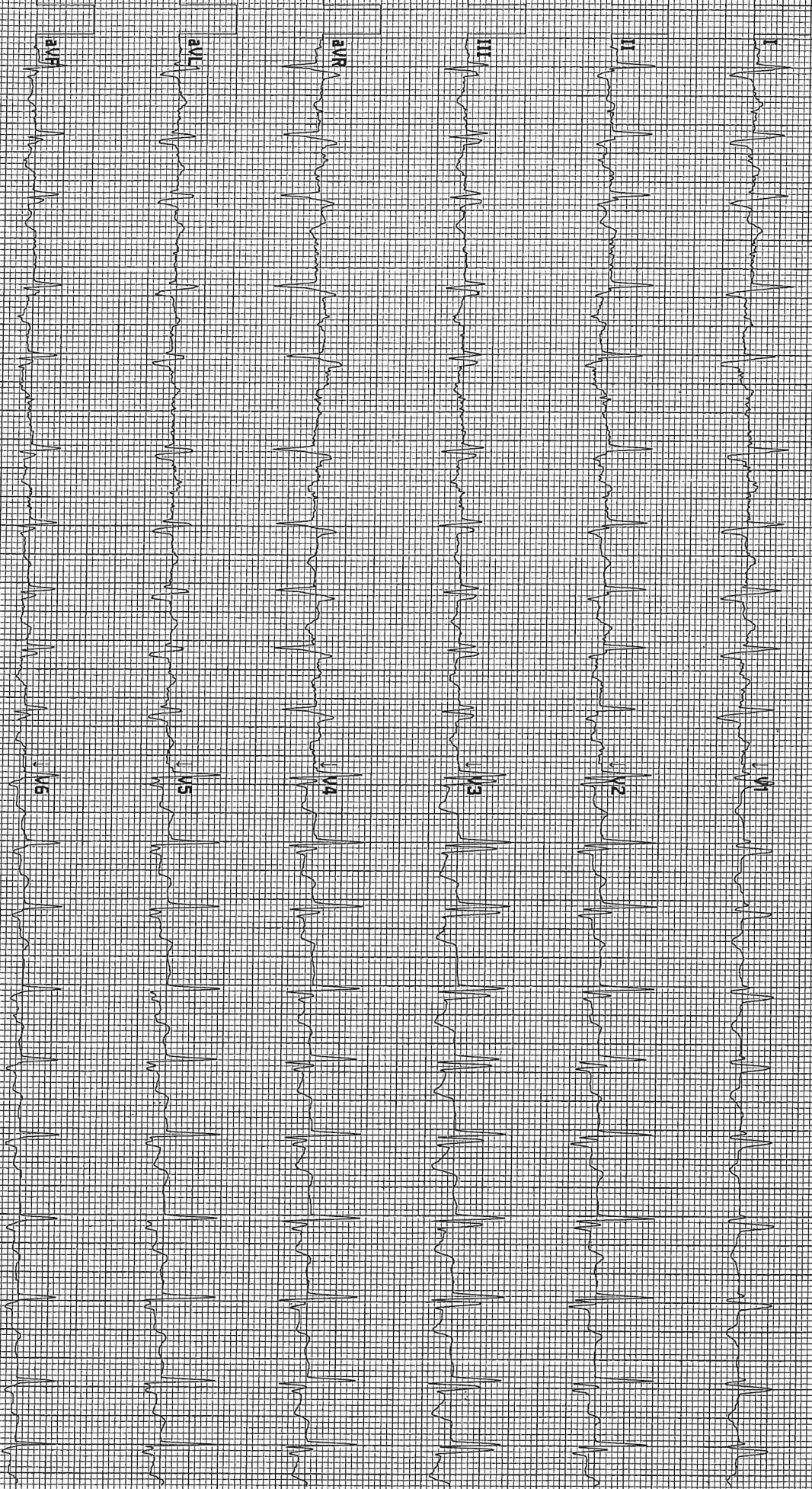
Prove estratte

Alessandro Ferla

A

GL





122070001785

SIT 40 CAP 0 R M ORT A R A U 9 1 0 0 5 8 9 2 7 2 0 5 0 3 8 2 5 m m / s 1 0 m m / m v 0.05-40 HZ M

fk

Qu

[Signature]

[Signature]

16/09/24
 Prove eszatte Alexander Ferlic

PROVA PRATICA N. 2

CHETOACIDOSI DIABETICA: paziente di 46 anni, diabetica, da alcune ore vomito dolore epigastrico.

16/09/24

Prove non estratte

Alexandra Ferrer

Handwritten signature and initials. The signature is a stylized, cursive name, possibly 'Alexandra Ferrer', written in black ink. To the right of the signature are the initials 'A.F.' and 'R.F.' written in a similar cursive style.

R. M. Z.

ly

ACIDO-BASE 37.0 °C

pH	6.929 ↓	
pCO ₂	22.0 ↓	mmHg
pO ₂	41.1 ↓	mmHg
HCO ₃ ⁻ act	4.5	mmol / L
HCO ₃ ⁻ std	6.9	mmol / L
BE(B)	- 27.0	mmol / L
BE(ecf)	- 27.9	mmol / L
ctCO ₂	5.2	mmol / L

CO-OSSIMETRIA

Hct	50	%
tHb	17.1	g / dL
sO ₂	66.9	%
FO ₂ Hb	66.4 ↓	%
FCO ₂ Hb	0.1 ↓	%
FMetHb	0.7	%
FHHb	32.8 ↑	%

OSSIGENAZIONE 37.0 °C

BO ₂	23.6	mL / dL
p50	20.2	mmHg
ctO ₂ (v)	15.9	mL / dL

ELETTROLITI

Na ⁺	141.0	mmol / L
K ⁺	5.46 ↑	mmol / L
Ca ⁺⁺	5.3	mg / dL
Cl ⁻	99	mmol / L
AnGap	43.0	mmol / L

METABOLITI

Glu	663 ↑	mg / dL
Lac	5.03 ↑	mmol / L

↑, ↓ = Fuori range

.....


16/09/24

Prove non esatte

Alessandra Ferraro

PROVA PRATICA N. 3

STEMI: paziente di 48 anni diabetico, si presenta in pronto soccorso per dolore epigastrico.

Handwritten signature and initials in black ink. The signature is a large, stylized 'P' followed by 'G'. Below it are the initials 'G' and 'A'.

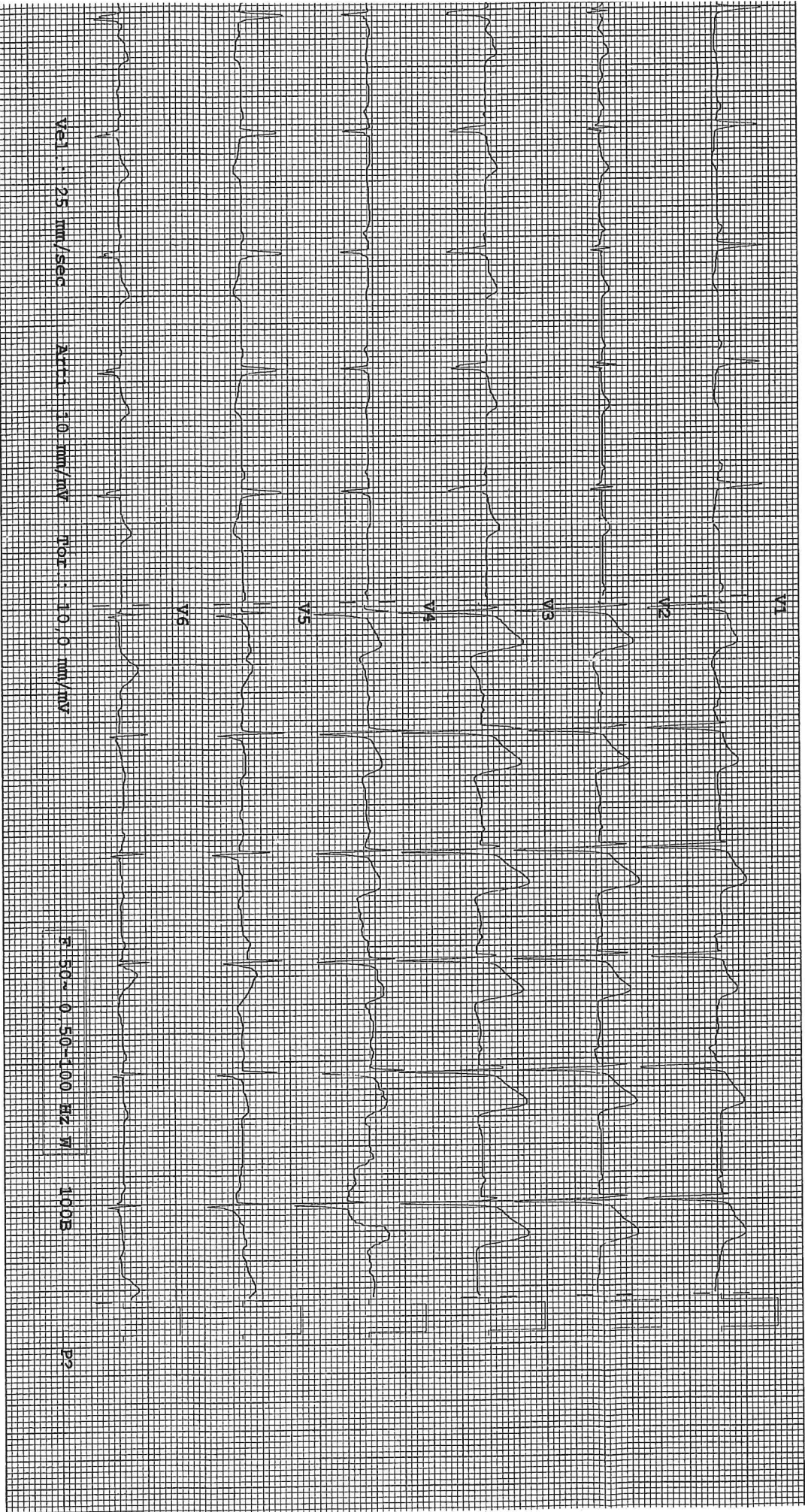
16/09/24

Prova non estesa
Assenza FET

1
0
2
1
6
19
14
17
; posizionamento standard



A handwritten signature and the initials 'K S' are present on the right side of the page.



71.830

26/09/24
Tracce non estratte
Alexandra Ferrero